



Wildlife Health Centre Newsletter

National Information Line 1-800-567-2033

Volume 12

Spring & Summer 2006

Number 1

In this issue:

Feature articles

- Canada's Inter-agency Wild Bird Influenza Survey—Results from 2005
- Devil's Lake Pathogen Surveys
- Wildlife Health Alert—Adenoviral Hemorrhagic Disease of Deer

Disease Updates

Atlantic Region

- Anticoagulant Rodenticide Toxicity in Birds
- Salmonellosis Returns to the Maritime Provinces' Passerine Bird Populations
- Skin Disease in Canada Geese
- Escherichia albertii* in Songbirds on Prince Edward Island

Quebec Region

- Illegal Shooting of Raptorial Birds in the Province of Quebec from 1986 to 2004
- Nocardiosis in a Juvenile Hooded Seal (*Cystophora cristata*)
- Autopsy of the Beluga Whales Necropsy Program: Two Decades of Data
- Schistosomiasis-related Mortality in Ring-billed Gulls

Ontario Region

- Common Toxicological Problems of Ontario Wildlife

Western/Northern Region

- Fenthion Poisoning in Black-billed Magpies (*Pica pica*)
- Demodocosis in a Mule Deer (*Odocoileus hemionus hemionus*) from Saskatchewan

Announcements

- First Charitable Donation
- Download your newsletter from our Website

Canada's Inter-agency Wild Bird Influenza Survey—Results from 2005

In the fall of 2005, a survey was undertaken to document the occurrence and distribution of influenza A viruses in Canadian wild birds. The survey was a collaborative effort among federal and provincial agencies responsible for agriculture, wildlife and public health and was coordinated by the CCWHC. Single cloacal swabs were collected from live birds between July and December 2005 from 6 regions across Canada: BC, Alberta, Manitoba, Ontario, Quebec, and the Atlantic Provinces (New Brunswick, Nova Scotia, Prince Edward Island and Newfoundland). The Canadian Wildlife Service (Environment Canada) was primarily responsible for the collection of samples which was carried out in conjunction with pre-planned research and banding activities in these areas.

Each cloacal swab was submitted to a primary laboratory within each collection region for initial testing. The six primary laboratories were: the Animal Health Centre - BC Ministry of Agriculture and Lands (Abbotsford, BC), Alberta Agriculture's Veterinary Diagnostic Laboratory (Edmonton, AB), Manitoba's Veterinary Services Branch - Ministry of Agriculture, Food and Rural Initiatives (Winnipeg, MB), the Animal Health Laboratory - University of Guelph (Guelph, ON), Quebec's INSA - Réseau des laboratoires - Ministère de l'agriculture, des pêcheries et de l'alimentation (St-Hyacinthe, QC), and the Atlantic Veterinary College - University of Prince Edward Island (Charlottetown, PEI).

All cloacal swabs were screened for the presence of influenza A viruses by real-time reverse transcriptase polymerase chain reaction (RRT-PCR) for the matrix protein (M1) gene sequence. If the M1 RRT-PCR result was positive or inconclusive, two more RRT-PCR tests were conducted to screen for the presence of H5 and H7 hemagglu-

tinin gene sequences. All samples that tested H5 or H7 RRT-PCR positive were sent directly to the National Centre for Foreign Animal Disease (NCFAD) in Winnipeg for virus isolation and further characterization. Virus isolation was also performed at the primary regional labs for all samples that tested M1 RRT-PCR positive but H5 and H7 negative. These isolates were then submitted to NCFAD for further characterization. Finally, the National Microbiology Lab (NML) was responsible for the sequencing of all viruses isolated by NCFAD and the primary laboratories. Below is a summary of the completed RRT-PCR test results.

A total of 4,268 samples with complete field data and RRT-PCR test results was collected from across Canada. Sampling began in July in Alberta and ended in December in Newfoundland. Eighty three percent (3,536/4,268) of all samples were collected in August. Thirty seven percent (1,572/4,268) of all cloacal swabs tested M1 positive by RRT-PCR. The proportion of M1 positive samples by region ranged from 10% (77/779) in Alberta to 55% (353/640) in British Columbia (Table 1). Four regions were responsible for the majority of M1 positive samples: British Columbia (22%), Ontario (22%), Quebec (24%) and the Atlantic Provinces (20%). Samples from the two prairie provinces contributed only 5% (Alberta) and 6% (Manitoba) of all M1 positive samples.

Seventy-three percent (1,148/1,572) of positive M1 RRT-PCR results were obtained from mallard ducks, 88% (1,388/1,572) were from juvenile ducks hatched in 2005 and 58% (914/1,572) were male. By univariate analysis, mallards were 2.3 (95% CI 2.0-2.7) times more likely to test positive by M1 RRT-PCR than other duck species, juvenile ducks were 2.3 (95% CI 1.9-2.9) times more likely to test positive than adult ducks, and males were 1.2 (95% CI 1.0-1.3) times more likely to test positive than females.

No samples tested positive for influenza A subtype H7. Five percent (208/4,268) of all samples and 13% (208/1,572) of M1 RRT-PCR positive samples tested positive for influenza A subtype H5. Of the 208 H5 positive samples, 77% (161) were from BC, 14% (28) from Quebec, 4% (9) from Ontario, 3% (6) from the Maritime Provinces and 2% (4) from Manitoba. No samples from Alberta or Newfoundland tested positive for hemagglutinin subtype H5. Sixty-four percent (133/208) of H5 positive birds were male, 99% (205/208) were juvenile birds, and 90% (187/208) were mallards or mallard/black duck hybrids. By univariate analysis, juvenile ducks were 7.2 (95% CI 2.5-28.7) times more likely to test positive by H5 PCR than older ducks, and mallards were 3.7 (95% CI 2.4-6.1) times more likely to test positive by H5 PCR than were other species of waterfowl.

Table 1: Number of valid records and positive RRT-PCR results by region

Province	Total samples	Matrix PCR positive	H5 PCR positive
British Columbia	640	353 (55%)	161 (25% of total, 46% of M1 positive samples)
Alberta	779	77 (10%)	0
Manitoba	524	94 (18%)	4 (1% of total, 4% of M1 positive samples)
Ontario	769	340 (44%)	9 (1% of total, 3% of M1 positive samples)
Quebec	781	382 (49%)	28 (4% of total, 7% of M1 positive samples)
Atlantic provinces	775	326 (42%)	6 (1% of total, 2% of M1 positive samples)
Total	4268	1572 (37%)	208 (5% of total, 13% of M1 positive samples)

Devil's Lake Pathogen Surveys

In June 2006, the CCWHC was asked by Environment Canada to become an active participant in joint Canada-US studies to assess the risks to the Red River drainage system posed by pathogens that may be present in Devil's Lake (North Dakota) and thus may be discharged into the Red River system if waters from Devil's Lake are released. In Canada, the commercial fishery on Lake Winnipeg, worth about \$30M annually, substantial First Nations harvests and an important sport fishery all potentially are at risk from pathogens introduced into the Red River system. Thus, the Ecosystem Committee of the International Red River

Board has organized a survey of fish parasites and pathogens within the Red River system, Lake Winnipeg and Devil's Lake. In Canada, the survey is being carried out cooperatively by Fisheries and Oceans Canada, the University of Manitoba and the CCWHC, and in the United States by the US Fish and Wildlife Service. In 2006, John Lumsden (CCWHC - Ontario/Nunavut Regional Centre, Ontario Veterinary College) will assess histological lesions and bacterial and viral pathogens in fish from Lake Winnipeg, and Craig Stephen and Ted Leighton (CCWHC - BC and SK) will work on establishing a risk analysis framework to guide the survey in 2007 and 2008.

Wildlife Health Alert

Adenoviral Hemorrhagic Disease of Deer

In mid-August, formalin-fixed tissues were submitted to the Western/Northern Regional Centre of the CCWHC from two mule deer fawns found dead in the townsite area of Waterton Lakes National Park in southwestern Alberta. Beginning in July and continuing through the month of August, a total of nine fawns died in the townsite. Fawns seen while alive had signs of respiratory distress. At necropsy, the most striking finding was severe lung edema with excess fluid in the chest cavity. One fawn also had hemorrhage and edema about the mesenteric lymph nodes.

The most prominent microscopic changes were severe pulmonary edema with evidence of degenerative and inflammatory changes in small vessels in the lung and elsewhere. Intracellular inclusion bodies were evident within cells lining blood vessels in several organs. On the basis of the gross and microscopic pathology, a tentative diagnosis of acute adenovirus infection was made.

Because only fixed tissue was available, confirmation was done using immunohistochemistry. Dr. Leslie Woods, at the University of Wyoming, who originally discovered adenoviral hemorrhagic disease (AHD) in California, generously agreed to examine the specimens using a monoclonal antibody prepared against virus isolated from deer in California. Tissues also were tested in Saskatoon using antibody to bovine adenovirus 5, that is known to cross-react with the deer virus. Both tests were positive for adenovirus antigen. Endothelial cells of blood vessels were the main cell type that stained positively.

This the first time that AHD has been diagnosed in free-ranging deer in Canada.

AHD was first recognized during an outbreak that killed thousands of deer in California in 1993 (Woods et al. 1996). Examination of archived tissues revealed that adenovirus also was involved in an earlier outbreak in 1987 in California (Woods 2001). AHD occurred in wild black-tailed deer in Oregon in 2001 and killed an estimated 400+ black-tailed deer in one area of Oregon in 2002 (Oregon Department of Fish and Wildlife). AHD has been diagnosed in captive black-tailed deer in California (Boyce et al. 2000), white-tailed deer in Iowa (Sorden et al. 2000), and moose in the Toronto Zoo (Shilton et al. 2002).

There is relatively little known about AHD. A factor that complicates understanding the distribution and significance of AHD is that the disease is indistinguishable from hemorrhagic disease in deer caused by two other viruses (Epizootic hemorrhagic disease (EHD) virus and Bluetongue virus), unless complete laboratory testing is done. Hemorrhagic disease occurs rather widely in the USA, and is usually thought to be caused by EHD and/or bluetongue virus. However; AHD would not be detected in these outbreaks without specific laboratory testing. Hemorrhagic disease is very rare in Canada. Approximately 400 white-tailed and mule deer

died in southeastern Alberta in 1962, and about 10 white-tailed deer died in the Okanagan Valley, British Columbia in 1986. EHD virus was identified in both outbreaks (Dulac et al. 1992).

It is thought that transmission among deer is by direct contact, but the source of infection is unknown. Clinical signs described in California and Oregon included rapid breathing, perhaps with the mouth open, foaming at the mouth, diarrhea that may be bloody, weakness, seizures and recumbency. At necropsy the most obvious pathology is excess fluid in the body cavities, especially the chest and lungs. There was particularly high mortality of young deer in California, but deer of all age and sex classes died in Oregon. There is no evidence that AHD represents a risk to traditional livestock or humans.

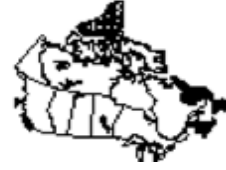Because this is the first recognition of AHD in Canada, it is important that suspected cases are examined to establish the cause. Young deer with evidence of severe respiratory difficulty, or animals found dead with no obvious cause evident should be considered suspect. If possible, the intact carcass should be kept cool until submitted to a diagnostic laboratory. Where this is not practical, the animal can be necropsied in the field. Digital photographs of the lesions are very helpful. Small portions of lung, liver, spleen, kidney, heart, intestine and lymph nodes should be preserved in 10% buffered formalin and unpreserved samples of lung, lymph nodes and spleen (in separate bags) should be kept cold until submitted to the laboratory. (Gary Wobeser—CCWHC)

References:

- Boyce, W.M. et al. (2000) An epizootic of adenovirus-induced hemorrhagic disease in captive black-tailed deer (*Odocoileus hemionus*). *J Zoo Wild Med.* 31:370-373
- Dulac, G.C. et al. 1991. Incursions of oribiviruses in Canada and their serologic monitoring in the native animal population between 1962 and 1991. In: Bluetongue, African horse sickness and related oribiviruses, T.E. Walton and B.I. Osburn, ed., CRC Press, Boca Raton, pp128-139.
- Oregon Department of Fish and Wildlife. Adenovirus hemorrhagic disease of deer Information sheet: available at <http://www.dfw.state.or.us/ODFWhtm1/InfoCntrWild/adenovirus.htm>
- Shilton C.M et al. (2002) Adenoviral infection in captive moose (*Alces alces*) in Canada. *J Zoo Wildl Med* 33:73-79
- Sorden S.D. et al. (2000) Fatal pulmonary edema in white-tailed deer (*Odocoileus virginianus*) associated with adenovirus infection. *J Vet Diagn Invest* 12: 378-380
- Wood, L.W. et al. 1996. Systemic adenoviral infection associated with high mortality in mule deer (*Odocoileus hemionus*) in California. *Vet Pathol* 33:125-132.
- Woods L.W. et al. 1999. Lesions and transmission of experimental adenovirus hemorrhagic disease in black-tailed deer fawns. *Vet Pathol.* 36:100-110
- Woods, L.M. 2001. Adenoviral diseases. In: Infectious diseases of wild mammals, 3rd edn, E.S. Williams and I.K. Barker, ed., Iowa State University Press, Ames, pp. 202-211.

DISEASE UPDATES

Atlantic Region



Anticoagulant Rodenticide Toxicity in Birds

There is growing concern within the wildlife community over increasing mortality associated with secondary poisoning by anticoagulant rodenticides, particularly the poisoning of raptors, such as red-tailed hawks (*Buteo jamaicensis*), and of scavenging birds. Exposure, in these instances, most likely occurs when a bird preys upon or scavenges another animal that has ingested poisoned bait. While a single exposure to a large enough amount of these rodenticides can be fatal, the second generation anticoagulant rodenticides (e.g. brodifacoum) are known to persist in the body. Thus, in the event of repeated exposure to sublethal amounts, bioaccumulation of a sufficient quantity of the poison to cause death can occur. Therefore, in suspicious cases (i.e., marked hemorrhage without obvious trauma), it is important to rule out possible exposure to an anticoagulant rodenticide.

In 2004, an adult male crow was submitted for examination with a history of potential exposure to rat poison and injuries consistent with anticoagulant rodenticide toxicity (i.e., extensive internal hemorrhaging with no evidence of significant trauma). Based on the advice of individuals more commonly involved with diagnosing acute rodenticide toxicity in domestic animals, the crow's stomach content was collected and submitted for testing. Subsequently, it was determined that rodenticides such as brodifacoum, bromadiolone, pindone, warfarin, chlorphacinone and diphacinone, if present in the stomach content, were not above the test's detection level of 0.5 ppm. Following a review of the pertinent literature and consultation with experts in this field, two salient points emerged. First, a minimum detection level of 0.5 ppm is not sufficient to confirm a diagnosis of anticoagulant rodenticide toxicity in birds because levels as small as 0.03 ppm, with a mean of 0.36 ppm, of brodifacoum in the liver have been associated with mortality in raptors (Stone et al, 2003. Bull. Environ. Contam. Toxicol. 70:34-40). Second, since death from rodenticide toxicity typically takes more than 5 days to occur, anticoagulant residues are often no longer present in the digestive tract at the time of death, except in rare instances when a bird has continuous access to, and regularly ingests, the anticoagulant compound. As a result, the liver is the preferred tissue for toxicological analysis in avian necropsy cases as the active anticoagulant compounds selectively bind to liver cells. Unfortunately, in this particular case the liver of the crow was discarded at the time of post mortem so a diagnosis of anticoagulant rodenticide toxicity could not be confirmed. The purpose of this short note is to prevent others from

repeating similar errors in avian cases where anticoagulant rodenticide toxicity is the suspected cause of death.

[Contributor: Scott McBurney, CCWHC Atlantic Region]



Salmonellosis Returns to the Maritime Provinces' Passerine Bird Populations

As in the winter and spring of 1997-98 (Wildlife Health Centre Newsletter, 1998, 5(2): 5-6), but to a much lesser extent, mortality of passerine birds due to salmonellosis, caused by the bacterium *Salmonella*, was recently documented over a wide geographical region of Nova Scotia and New Brunswick. *Salmonella* bacteria are commonly found in the gastro-intestinal tracts of many wild and domestic bird species. Disease can occur during periods of stress, such as severe cold and reduced food sources. Under these conditions the disease can spread particularly rapidly around those sources of food that are still available, such as bird feeders, due to the high concentration of birds at these sites. In this particular event, several species were affected including common redpolls (*Carduelis flammea*) and pine siskins (*C. pinus*) and submitted for examination during the months of March and April 2006. While there are many types of *Salmonella* bacteria, the most common in songbirds is known as *Salmonella typhimurium* which was isolated from the submitted birds in this case. This serotyping can be further refined, making it possible to identify distinct phagetypes. In this case the serotyping and phage typing of the *Salmonella* isolates has not been completed, but 160 is the phage type identified in several of the cases thus far. Interestingly, *S. typhimurium* phage type 40 was the most common isolate in the previous epizootic of salmonellosis in the Atlantic region, and phage type 160 was more typically reported to be associated with sporadic winter mortalities among house sparrows (*Passer domesticus*) in Ontario (Prescott et al., 1998, Veterinary Record, 142: 732). Serotyping and phage typing results from the other *S. typhimurium* isolates collected during this spring are eagerly awaited. (Contributors: Scott McBurney, CCWHC, Atlantic Region; James Goltz, Provincial Veterinary Laboratory, Fredericton, New Brunswick; Grant Spearman, Veterinary Pathology Laboratory, Truro, Nova Scotia).

Skin Disease in Canada Geese

In the fall of 2005, at approximately the same time of the year, a number of Canada Geese (*Branta canadensis*) with identical skin conditions were submitted from two different areas of the Maritimes: one in western Prince Edward Island (seven birds submitted by a professional plucker), and the other in New Brunswick (one bird submitted by a hunter). These two locations are across from one another on either side of the Northumberland Strait, separated by a

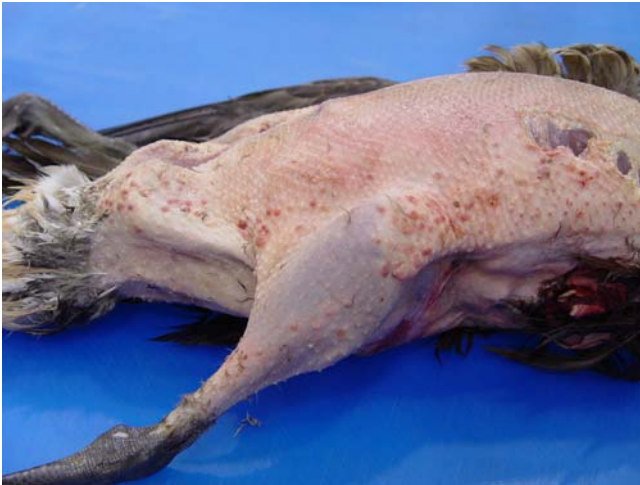

Figure 1

distance of roughly 100 km. The skin of these birds consisted of numerous small pimple-like nodules concentrated mainly along the sides of the abdomen and extending along the legs (Figure 1). Some of these nodules looked red and inflamed, while others were the same color as the skin. Upon microscopic examination, many nodules appeared to be centered in proximity to the remnants of feather follicles (out of which individual feathers normally grow). Furthermore, nodules, even those found on the same bird, displayed different characteristics, some were inflamed while others were apparently healed, being composed only of scar tissue. Interestingly, none of the geese showed any evidence of feather loss and all the birds were otherwise in good body condition, with adequate fat reserves. The majority of geese that could be aged were determined to be hatch-year birds. In addition to the geese, one hatch-year black duck with similar lesions was also submitted from PEI. Both the plucker and the hunter commented that in their 20 plus year's experience they have never encountered a similar case. The plucker estimated that roughly 15-20% of the birds that he had received showed this skin condition, adding that even though these birds seemed otherwise healthy, the plucked carcasses were rejected by the hunters because of their unsightly appearance.

Unfortunately, the cause of this skin problem could not be determined and, at present, no possibility as to the cause, whether it be infectious, such as a virus or a microscopic parasite, or even toxicological can be discounted. More-

over, because these birds were on their fall migration, the problem could have originated somewhere else further north. We will be watching closely this coming fall for a potential recurrence of this phenomenon.
(Pierre-Yves Doust, CCWHC)



Escherichia albertii in Songbirds on Prince Edward Island

In winter 2004-05, a study was initiated to determine the prevalence of the bacterium *Salmonella* in Prince Edward Island songbirds. The associated disease, salmonellosis, is an infection that can cause mortality in a variety of songbird species, particularly at feeders during the winter season. With the help of certified bird banders, we captured songbirds of three species: 33 Common Redpolls (*Carduelis flammea*), 40 Purple Finches (*Carpodacus purpureus*), and 95 Pine Siskins (*Carduelis pinus*). Fecal samples were collected from each bird. The birds were then banded and released. Although no *Salmonella* was isolated the growth of bacterial colonies with a similar appearance from several of the samples (11 Pine Siskins, 4 Common Redpolls) called for closer examination. All 15 isolates turned out to be those of a newly identified species of bacterium known as *Escherichia albertii* (confirmed by the Laboratory of Dr. J.L. Oaks, at Washington State University), which caused an outbreak of mortality in Common Redpolls in Alaska in 2005 (<http://www.promedmail.org> - Archive number 20050309.0695). In winter 2005-06, we collected fecal samples from 142 Common Redpolls and 4 Purple Finches. *Escherichia albertii* was not isolated from any of these birds, but *Salmonella* was isolated from two Common Redpolls.

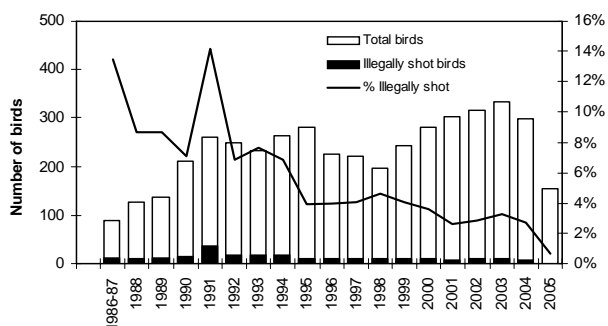
Escherichia albertii was first identified in association with diarrheal disease in children from Bangladesh in 2003 (International Journal of Systematic and Evolutionary Microbiology 53:807-810, 2003). To date, the only report of disease associated with *E. albertii* in animals is the mortality event in Common Redpolls in Alaska, already referred to. However, the isolate from these birds appeared very similar to an atypical *E. coli* previously associated with finch mortality in Scotland (Letters in Applied Microbiology 26:395-398, 1998). These observations and the identification of this bacterium in songbirds from PEI suggest that it is widespread in this group of birds and, like *Salmonella*, may cause disease under the right circumstances, such as stressful environmental conditions in winter. (Greg Dobbin, Pierre-Yves Daoust and Mada Coles, Atlantic Veterinary College)



Illegal Shooting of Raptorial Birds in the Province of Quebec from 1986 to 2004

A review of cases involving free-ranging birds of prey admitted to the University of Montreal's *Faculté de médecine vétérinaire* between 1986 and 2004 was recently undertaken. The purpose of the review was to evaluate the occurrence of illegal shooting of birds of prey in Quebec and track the incidence of this illegal activity over time. Analysis revealed evidence of gunshot in 276 cases (6.2% of the 4432 birds admitted and 10.5% of the 2635 radiographed birds). It was further revealed that large birds, which frequently fly in open areas, were the most frequently shot. This includes birds such as turkey vultures (12/33), ospreys (37/113), snowy owls (35/191), bald eagles (10/58) and rough-legged hawks (22/137). Further analysis showed that the percentages of shot raptors has declined steadily over time (Figure 2), which suggests a decrease in the intensity of illegal shooting of raptors in the province. Potential reasons for this trend include a decrease in the presence of firearms in raptor habitat (decrease of hunting licenses over the years) and positive changes in public attitudes toward raptorial birds. The educational outreach program led by a provincial organization dedicated to raptor conservation (*Union québécoise de réhabilitation des oiseaux de proie*) over this period may have accounted, at least in part, for the improvement observed. Due to sampling bias, the significance of shooting as a cause of mortality in the general population of birds of prey is difficult to determine.

Figure 2. Free-ranging birds of prey admitted at the *Faculté de médecine vétérinaire* with and without evidence of illegal shooting (n=4432).



Stéphane Lair, Ariane Santamaria-Bouvier and Guy Fitzgérald (CCWHC Quebec).

(Aussi disponible en français)

Nocardiosis in a Juvenile Hooded Seal (*Cystophora cristata*)

Hooded seals (*Cystophora cristata*) live in the North Atlantic Ocean where their population is believed to be between 400,000 to 500,000 individuals. They give birth during the spring on ice packs in the Gulf of St. Lawrence, in Davis Strait and east of Newfoundland. Interestingly, the nursing of hooded seal pups lasts for an average of only 3.8 days, the shortest lactation period of any mammal. Hooded seals, especially juvenile animals, are frequently encountered outside their normal distribution range, including in the St. Lawrence River. This was the case during the summer and fall of 2005 when several hooded seals were reported wandering upstream of Quebec City. One of these animals was observed around Montreal for about one week before it was found beached alive in the Port of Montreal. Due to its very poor body condition and because of the risks associated with its presence in this very busy area, the animal was removed. The animal in question, a juvenile male, had an inflammation of the conjunctiva of both eyes and a mild purulent nasal discharge. Blood analysis revealed an elevated white blood cell count. Upon post-mortem analysis, numerous circular whitish foci, ranging in diameter from 2 to 4 mm, were present in the lung, spleen and liver (Figure 3). The gastric and tracheobronchial

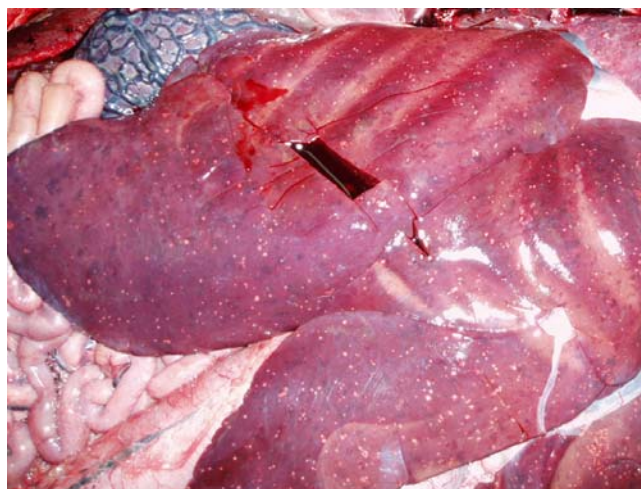


Figure 3. Numerous necrotic foci observed in the liver of a hooded seal affected by nocardiosis (René Roy).

lymph nodes were enlarged. On microscopic examination, numerous areas of necrosis (cellular death) infiltrated by numerous degenerate neutrophils (inflammatory cells)

surrounded by several rows of vacuolated macrophages were seen in the liver, lung, lymph nodes, spleen and brain. Numerous filamentous and branched Gram positive rods with a "beaded" appearance were present in the necrotic foci. These bacteria were also stained by a modified acid fast stain (Fite-Faraco stain) (Figure 4), but

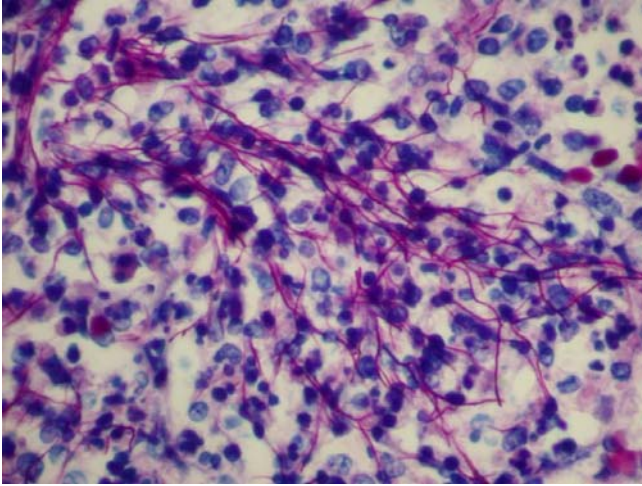


Figure 4. Filamentous rods in the liver of a hooded seal stained with a Fite-Faraco stain. The morphology and staining propriety of these bacteria are suggestive of *Nocardia* sp.

were not stained by a standard acid fast stain (Ziehl-Neelsen). Upon further analysis *Nocardia otitidiscaviarum* was identified in the liver, spleen, lung, brain, and lymphatic nodes (identification was made by 16S ribosomal DNA sequence analysis).

Infections by *Nocardia* spp. (known as nocardiosis and primarily affecting the lungs), particularly *N. asteroides*, have occasionally been reported in cetaceans, although mainly in a captive setting.² One of the cases of nocardiosis in a wild cetacean was described in a beluga whale from the St. Lawrence Estuary.³ We are aware of only one report of nocardiosis in a pinniped,⁴ however there have been other un-published cases described in hooded seals found stranded on the Atlantic coast of the USA. *N. otitidiscaviarum* (previously known as *N. cavia*) is an organism encountered in the environment that has been associated with infections of the skin, central nervous system, and lung in people.¹ As far as we know, this bacterium has never been implicated in a case of nocardiosis in marine mammals. Immunosuppression has been identified as an important risk factor for infection by *N. otitidiscaviarum* in people.¹ Due to the relative acuteness of the lesions observed in this animal, we believe that this disease was a consequence rather than the cause of the erratic migration and poor body condition observed in this seal.

(Aussi disponible en français)

References:

1. Beaman, B. L., and L. Beaman. 1994. *Nocardia* species: host-parasite relationships. *Clin. Microbiol. Rev.* 7: 213-264.
2. Dunn, J. L., J. D. Buck, and T. R. Robeck. 2001. Bacterial diseases of cetaceans and pinnipeds. *In: Gulland, F. M. D., and L. A. Dierauf (eds). CRC Handbook of Marine Mammal Medicine. 2 ed. CRC Press LLC, Boca Raton, Florida. Pp. 309-335.*
3. Martineau, D., A. Lagacé, P. Béland, R. Higgins, D. Armstrong, and L. R. Shugart. 1988. Pathology of stranded beluga whales (*Delphinapterus leucas*) from the St Lawrence Estuary, Quebec. *J. Comp. Pathol.* 98: 287-311.
4. Sweeney, J. C., G. Migaki, P. M. Vainik, and R. H. Conklin. 1976. Systemic mycoses in marine mammals. *J. Am. Vet. Med. Assoc.* 169: 946-948.

Stéphane Lair, and André D. Dallaire (CCWHC Quebec).
René Roy (LÉPAQ, Ministère de l'Agriculture des Pêcheries et de l'Alimentation, Sainte-Foy, Québec, Canada).



Autopsy of the Beluga Whales Necropsy Program: Two Decades of Data

A review of the St. Lawrence Estuary carcass program was held in the fall of 2005 in the form of a workshop, organized by Fisheries and Oceans Canada. During the workshop a summary of 20 years of data from the St. Lawrence beluga whale pathology program was presented. Between 1983 and 2004 a total of 318 beluga carcasses from the St. Lawrence Estuary (SLE) population were reported stranded or drifting, of these, 166 carcasses (85 males, 79 females and 2 intersexes) underwent postmortem examination. Standard necropsies were conducted on each carcass using an evolving but uniform protocol. Degree of autolysis was estimated using carcass classification codes proposed by Geraci and Lounsbury (1993) either at the time of the examination or retrospectively, based on the postmortem report. Samples for further diagnostic analysis were routinely collected in each case.

The review showed that beluga carcasses were often poorly preserved, with 41% of the carcasses given decomposition codes of 2.5 or higher (decomposed to advanced decomposition). Failure to identify a presumed cause of stranding increased as the degree of decomposition increased; the cause of stranding was not determined in 15%, 34% and 57% of the relatively fresh carcasses (codes 1 and 2), moderately decomposed carcasses (codes 2.5 and 3), and markedly decomposed carcasses (codes 3.5 and 4), respectively. Analysis also

revealed that the percentage of cases for which a presumed cause of stranding was determined increased throughout the years, from 58% in the first 4 years to 85% in the last 4 years. Presumed causes of stranding were determined by the pathologist based on his/her interpretation of *postmortem* findings. Table 1 presents the presumed causes of stranding for four different age groups.

Overall, infectious diseases were the most common causes of stranding. Verminous pneumonia (caused by the nematodes *Halocercus* sp. or *Stenurus arctomarinus*) was the presumed cause of death in 15% of all cases, with a higher prevalence in juvenile animals (1-7yr), in which verminous pneumonia was the presumed cause of stranding in 49% of cases. Other fatal parasitic diseases include 4 cases of nematode-associated perforated ulcers of the gastro-intestinal tract and 2 cases of toxoplasmosis, a disease caused by a protozoan parasite. Presumably fatal bacterial infections, such as abscesses, bacterial pneumonia and septicaemia (bacteria in the blood stream), were diagnosed in 19% of the sampled belugas. The

bacterial isolates associated with these fatal bacterial infections included: *Aeromonas* sp., *Clostridium* sp., *Edwardsiella tarda*, *Escherichia coli*, *Klebsiella oxytoca*, *Morganella morganii*, *Nocardia* sp., *Pseudomonas putrefaciens*, *Streptococcus* sp. and *Vibrio* sp.

A total of 31 malignant neoplasms (cancer) were diagnosed in 28 of the 126 adult (>7yr) beluga examined (mean estimated age [range] = 21 [11 – 30]yr). The prevalence at death of malignant neoplasms in adult animals (>7yr) was 20%. These cancers are believed to have caused the death of 25 of the examined belugas.

Traumatic lesions, such as vertebral fractures, deep skin lacerations and pulmonary lacerations, were seen in 11 animals. Although the causes of these traumatic lesions could not be determined with certainty in all cases, they are believed to be most likely associated with boat strikes. Interestingly, 9 of the 11 cases of fatal traumatic injuries were seen after 1994.

Stéphane Lair (CCWHC Quebec).

Table 2. Presumed causes of stranding in St. Lawrence beluga whales from 1983 to 2004.

Presumed causes of stranding - n (%)	Age groups ^a				TOTAL
	< 1yr	1yr – 7yr	8yr – 20yr	> 20yr	
Not determined	-	6 (26.1%)	17 (27.4%)	24 (37.5%)	47 (28.3%)
Perinatal mortality	9 (64.3%)	-	-	-	9 (5.4%)
Infectious – bacterial	2 (14.3%)	4 (17.4%)	13 (21.0%)	12 (18.8%)	32 (19.3%)
Infectious – parasitic	2 (14.3%)	12 (52.2%)	11 (17.7%)	5 (7.8%)	31 (18.7%)
Neoplasia	0 (0%)	0 (0%)	10 (16.1%)	15 (23.4%)	25 (15.1%)
Trauma	0 (0%)	1 (4.3%)	5 (8.1%)	5 (7.8%)	11 (6.6%)
Degenerative	0 (0%)	0 (0%)	2 (3.2%)	2 (3.1%)	4 (2.4%)
Dystocia	-	0 (0%)	3 (4.8%)	0 (0%)	3 (1.8%)
Other	1 (7.1%)	0 (0%)	1 (1.6%)	1 (1.6%)	4 (2.4%)
Total number of carcasses	14	23	62	64	166

^a Age not determined in 3 of the 166 beluga.



Schistosomiasis-related Mortality in Ring-billed Gulls

A person taking a walk along the shore of the St Lawrence in the Kamouraska area contacted the local wildlife office to inform them of numerous dead gulls seen close to the salt marshes. In total, 45 Ring-billed Gulls (*Larus delewarensis*) were found dead along the shore over a short distance. The birds were found lying along a line, as if transported simultaneously by the tide (Figure 5). The officer who investigated this case could not detect any obvious trauma, but did notice that silage was readily available to wild birds less than 400 meters away, raising the possibility of some form of intoxication.



Figure 5. Localization of Ringed-billed gulls found dead on the salt marshes along the St Lawrence in spring 2006.

Given the suspicious circumstances and the number of birds involved, local residents were concerned about the possibility of avian influenza being the cause of death. Thus eleven birds were submitted by the regional FAPAQ office to the CCWHC Québec Regional Center in Saint-Hyacinthe for complete post-mortem examination. All of the submitted birds were adults and included nine females and two males. The birds, which were rather well preserved, were emaciated and had minimal body fat stores. The eyeballs were often retracted deeply within their orbit, a condition suggestive of dehydration. In keeping with their emaciated state, the bird's gizzards were predominantly empty and the intestinal content was scarce, primarily comprised of liquid admixed with mucus. Avian influenza virus was not detected in any of these birds by PCR testing, nor was *Salmonella*, using standard bacterial culture. Further diagnostic examination revealed significant cell death by histological evaluation of tissues, and chronic inflammation of the intestinal wall, caeca and within the liver and kidney. These inflammatory foci usually contained degenerated parasites and eggs. Better preserved parasites could also be observed within the blood vessels adjacent to the intestine (Figure 6). Chronic inflammation was also noted along the wall of many small blood vessels within varied tissues. The morphology of these parasites was compatible with an intravascular trematode (*Schistosomatidae*).

Adult schistosomes are parasites of blood vessels of the digestive and urinary tracts of both birds and mammals. The life cycle of *Schistosomatidae* is such that the eggs are released with the feces, and usually hatch when they come into contact with water, at which time a small parasite precursor is released. This stage will enter a freshwater snail and develop in yet another intermediate form (cercariae). It is this form that will penetrate the skin of vertebrate hosts and will then migrate to the liver after passing through the lung. After some time, male and female schistosomes will move to the mesenteric veins and reproduce. The eggs will then make their way through the intestinal wall into the lumen and

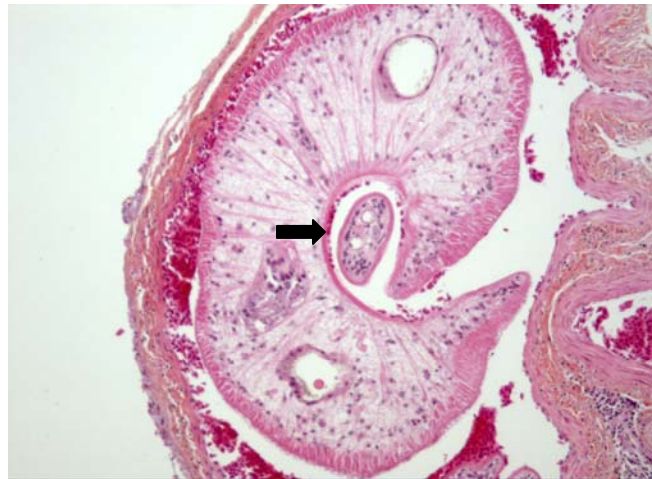


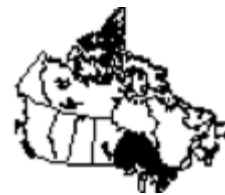Figure 6. A trematode parasite located in the lumen of a mesenteric vein adjacent to the intestine of a Ring-billed gull. The female trematode (black arrow) is being carried by the male (André Dallaire).

escape with feces. This passage through the intestine mucosa will cause chronic inflammation which will then favor the dissemination of the eggs to other tissues. This life history is rather similar for most species of schistosomes seen in birds and mammals.

The effect of these parasites on their avian hosts is not as well known as for humans or domestic animals. To the best of our knowledge, a mortality event related to this type of parasite along the St Lawrence has not been described before. Interestingly, a parasite from this group is also responsible for swimmer's itch in humans, which results in an allergic response after repeated skin penetration by cercariae, the intermediate form that emerges from the snail.

André D. Dallaire (CCWHC Québec)





Common Toxicological Problems of Ontario Wildlife

Although numerous causes of death exist, poisoning is often the first suspicion when an animal is found dead. Every year the CCWHC laboratory in Guelph diagnoses a considerable number of poisoning cases involving wildlife. As there is no all-purpose toxicological test available that will detect all toxic compounds in a sample, it is usually necessary to first have some rough guess as to what poison is likely involved in order to obtain a diagnosis of poisoning. Some methods, such as mass spectrophotometry and gas chromatography, have greatly increased the chances of detecting a toxic exposure, but in most instances, pathologists still need to have a suspicion of the specific material involved in each particular case and thus order the appropriate test that will detect it.

This article will outline a sampling of cases involving wildlife in Ontario and some of the more common toxicological exposures that we have detected in recent years.

Cholinesterase-inhibiting insecticides

Pesticides such as organophosphates and carbamates exert their action by inhibiting the action of enzymes that break down the neurotransmitter acetylcholine. In this manner, nerves which use this neurotransmitter will continue to fire and stimulate the tissues which they serve. This will affect many tissues, including the heart, brain and smooth muscle of the gut, resulting in the rapid death of the animal.

Poisoning with these compounds is detected in one of two ways: the compound itself may be detected in the stomach contents of the animal, or, more commonly, the activity of the cholinesterase enzyme in the brain is measured. If enzyme activity is reduced below 80% of normal, it is likely that the animal has been exposed to a cholinesterase-inhibiting pesticide. If activity is below 50% of normal, pesticide exposure is the likely cause of death. The difficulty is that many laboratories do not have normal values for species of wild birds, making it difficult to tell whether or not a measured value is normal.

Each year we have a few cases of waterfowl, typically Canada Geese, that consume one of these pesticides, often Diazinon. Exposure usually occurs while grazing on grass that has recently been treated for insect pests. These events typically happen during June and July when lawns are being treated and groups of geese are grazing on the affected area. In each of the years of 2004 and 2005, there were 3 incidents of this type, involving 6-17 birds per incident.

For many years there has been concern about the possibility of songbirds being exposed to pesticides in either agricultural or urban/suburban locations where these insecticides are in use on agricultural crops or lawns and gardens. Cases of individual birds found dead are rarely tested for insecticide exposure, but when groups of birds are found dead in one location, there is a higher index of suspicion that some form of poisoning could be responsible. In the past two summers, the lab has diagnosed pesticide poisoning in 3 incidents of this sort, one involving red-winged blackbirds, one with

pigeons and one with crows.

A review of cases from previous years revealed a number of similar events, involving a range of species including; grackles, starlings, cowbirds and ring billed gulls. In many of these, the cholinesterase testing was suggestive of poisoning, but not so depressed as to make the diagnosis definitive.

In addition, there have been 3 cases involving peregrine falcons in which there was significant brain cholinesterase depression. Cholinesterase levels in these 3 birds ranged from 2.0 – 13.0 IU/g/min compared with levels of 17.9-30.5 in 6 other peregrines. The suspicion is that the peregrines were intoxicated through the consumption of songbirds that had been exposed to insecticide. In all 3 of these birds, the ventriculus contained the remains of birds that had been consumed as prey.

Cholinesterase-inhibiting insecticides are occasionally employed in malicious poisonings involving wildlife. Recent case records include 3 cases in bald eagles in which brain cholinesterase levels were 25-50% of those of the single reference bird tested. In all of these cases, the birds had material in their upper digestive tracts which might have been bait used to deliver the poison. However, a specific compound was not identified in any of these cases, leaving them as suspicious or presumptive diagnoses.

More recently, a marten and two ravens were found dead close to one another, and a bag containing white powder was also found in the vicinity. All 3 animals showed depressed brain cholinesterase levels and the powder was identified as a carbamate insecticide.

Avitrol

Avitrol (4-aminopyridine) is a compound used in nuisance bird control and is delivered through bait, typically whole or chopped corn. It is described as a frightening agent that exerts its main effect on the brain of the bird. Under the influence of avitrol, birds behave erratically and emit alarm calls; this in turn causes the bird's flockmates to become alarmed and disperse, and in this way the flock is frightened away. Although avitrol is not intended to be lethal, birds can become disorientated resulting in accidents and death. Furthermore, birds can die of overdose if the corn bait is inadequately or improperly mixed, resulting in a lethal dose of the agent.

Since 1989, the Ontario region of the CCWHC has diagnosed 69 separate incidents involving avitrol poisoning. The number of birds involved in these incidents has ranged from single birds, which is the most common occurrence, to hundreds of birds seen sick or dead due to avitrol exposure. Pigeons, as a target species for bird control, are the birds most commonly involved in avitrol poisonings, but a range of other species, including mourning dove, crow, grackle, blue jay and, surprisingly, trumpeter swan and Canada goose, have been diagnosed. Most of these birds are likely poisoned accidentally when bait is put out for pigeons, but we have

now seen 3 separate larger scale incidents of poisoning of grackles or crows, which were possibly deliberate, off-label uses.

There has long been a concern over the possibility of secondary poisonings in which a predator might be exposed from eating an avitrol-intoxicated bird. Since 2001, we have tested 19 peregrine falcons for avitrol exposure. In 2 of these birds, trace amounts were detected, while quantifiable amounts were found in 5 other birds, all of whom had died of traumatic injuries. In addition, 1 merlin has been found with detectable avitrol in tissue. Although these birds are not exposed to directly lethal amounts of the compound, it seems reasonable to believe that any slight degree of disorientation could be fatal at the speeds achieved by birds of prey in flight.

Ethylene Glycol

Ethylene glycol, which is the main ingredient of antifreeze, has long been known as a common cause of poisoning of humans and domestic animals, but has not commonly been reported in wildlife. The metabolic breakdown of ethylene glycol in the body produces toxic metabolites which exert effects on many organs, including brain, kidney and heart, commonly resulting in death.

Domestic animals have commonly been exposed inadvertently, as for example when a person is changing the antifreeze in a vehicle and leaves some of the compound available in an open container or drainpan. However, it seems questionable whether wild animals are being exposed by this route, or whether the poisoning may instead be deliberate. In our case records, going back to 1994, we have 19 cases involving ethylene glycol poisoning. The majority involve either raccoons or skunks (12 raccoons, 4 skunks). There is also one case involving an opossum. While most of these cases have been from urban areas, there have been two unusual cases deriving from rural locations; one a turkey vulture and the other a black bear.

Rodenticides

The anticoagulant rodenticides, of which warfarin is the oldest, are some of the most commonly used poisons. Unlike warfarin, which required several exposures to be effective, the more recently developed rodenticides are more potent, requiring only a single exposure to be fatal. Although these compounds are designed and licenced to be used within buildings, they are sometimes used out of doors.

In our case records, we have a small number (10) of confirmed poisonings involving anticoagulant rodenticides and a great many more suspected cases. The laboratory test available to us is not highly sensitive, and many cases test negative when the post-mortem evidence leads to a high suspicion of poisoning. Of these confirmed cases, 5 involved Bromadiolone, 3 were Brodifacoum and 2 were Warfarin.

Six of the cases involved grey squirrels, which also made up the bulk of the suspected, but unconfirmed, cases, and one case involved a number of short-tailed shrews. There has long been concern involving the potential for secondary poisoning with these compounds, in which a predator or scavenger might be exposed through eating a poisoned

rodent. In some localities such poisonings have been documented in raptors. In our case records, there is one raccoon and 2 crows, all of which may have been poisoned after consuming the carcass of an affected rodent. We have never documented anticoagulant rodenticide in a raptor.

Zinc phosphide is a rodenticide commonly used in outdoor pest control. We have had 4 cases of zinc phosphide poisoning: 3 of these involved groups of Canada geese, the fourth a group of wild turkeys. Two of the episodes involving geese were on landscaped properties at an industrial park, while the third was at a golf course. The turkeys were poisoned in an apple orchard.

Lead

Lead is a well-known and long-standing potential source of toxic exposure for wildlife. The use of lead in shot used for waterfowl hunting has now been banned, and there are localized restrictions on its use in fishing tackle. Thus it may be expected that the number of birds poisoned with lead will decline over time. However, it remains one of the most common poisonings diagnosed at our laboratory.

In the period 2000-2005, there were 52 confirmed incidents of lead poisoning. Trumpeter swans are the birds most commonly involved (27), with common loons (10), Canada geese (5), other waterfowl (4), bald eagles (5) and a peregrine falcon making up the remainder of the cases. Waterfowl typically are poisoned by picking up spent lead shot from hunting, and some popular hunting areas are likely badly contaminated from years of hunting activity. Common loons typically are poisoned from ingesting lead fishing weights. The source of lead for bald eagles is largely unknown, but in the past it was thought that they obtained lead from scavenging injured waterfowl. With the ban on lead shot for waterfowl hunting, this should no longer have been the case. The peregrine falcon is even more puzzling. The case involved a young of the year bird from Burlington. Tissue levels in liver and kidney were markedly elevated (23 and 28 ppm wet weight, respectively), indicating a substantial exposure.

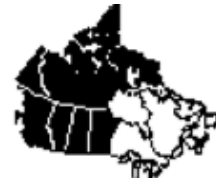Submitting cases for toxicology testing

Communication is an important part of the laboratory component of an investigation of a suspected poisoning of wildlife. The location, circumstances, time of year, observed behavior of the animals involved, all of these aspects are important in evaluating the possible causes of death.

Even if poisoning is high on the list of possibilities, the pathologist will usually do a complete necropsy examination to eliminate other causes of death. It is important to remember that many tests are quite specific, and it is necessary to have a particular toxin in mind in order to have any chance of a positive result.

If poisoning is suspected in a wildlife mortality incident, it is a good idea to begin with a phone call or email to the regional laboratory, in order to discuss the possible causes, and perhaps to obtain suggestions on sample collection and handling.

Doug Campbell (CCWHC Ontario/Nunavut Region)



Fenthion Poisoning in Black-billed Magpies (*Pica pica*)

On the 6th of April 2006 a farmer in west-central Saskatchewan reported several dead black-billed magpies near his cattle feedlot. The owner was unaware of any use of poisons in the area and the farm dog that roamed the area had not been ill. Nine birds were subsequently collected within a small area by the local conservation officer and submitted to the Western/Northern Regional CCWHC centre in Saskatoon for further analysis. Four of these birds initially were necropsied with the others being held frozen. Initial analysis showed nothing unusual, with the birds being in moderate body condition. However, brain cholinesterase activity ranged from 8 to 21% of normal, a finding consistent with acute toxicity and death associated with exposure to an anticholinesterase agent. On further questioning, the farm owner recalled treating his cattle for lice with topical insecticide on the 26th of February. The compound used to treat the cattle contained the active ingredient fenthion, an organophosphate insecticide. Material collected from the esophagus of two of the birds that had been kept frozen contained elevated levels of fenthion. In this instance, it is not known when the birds died; they may have died shortly after use of the compound and been frozen under the snow, or they may have been exposed shortly before they were found, as fenthion remains active in the environment for some time. This is the fourth instance in the past 15 years in which we have diagnosed fenthion poisoning in magpies in association with its use on livestock. Fenthion poisoning of magpies was first reported in 1981 (Hanson and Howell 1981, Canadian Veterinary Journal 22:18-19) and poisoning with another organophosphate used for treating cattle (famphur) also has been reported (Henny et al. 1985, Journal of Wildlife Management 49: 648-658).

The registrant for fenthion in Canada has voluntarily discontinued all products and uses, and the registration for all fenthion products will expire 31 December, 2006 (Pest Management Regulatory Agency, Health Canada RRD2004-10).

Gary Wobeser, Canadian Cooperative Wildlife Health Centre and Brett L. Diemert, Saskatchewan Environment.



(Aussi disponible en français)

Demodecosis in a Mule Deer (*Odocoileus hemionus hemionus*) from Saskatchewan

In March 2006, a female mule deer was found dead approximately 20 km northeast of Saskatoon. The deer had extensive hair loss around the eyes, the sides of the head, the flanks, hind limbs, and rump. With the exception of the rump, where the skin was dry and covered with flaky white scales, the skin was generally dark grey, moist and slightly thickened, with sparse short hairs remaining on the flanks. Based on tooth replacement and wear, the animal's age was estimated to be between 1.5 and 2 years. It was in poor nutritional condition with little to no body fat. Nothing abnormal was observed in any tissues other than the skin. Because ringworm (*Trichophyton verrucosum*) infection is relatively common in mule deer in Saskatchewan and can cause similar changes, samples of hair plucked from the margins of affected areas were prepared as wet mounts and examined under light microscope. No fungal spores were seen. The deer tested negative for Chronic Wasting Disease.

Microscopically, all affected areas of skin were similar with dilated hair follicles and sebaceous glands filled with large numbers of cigar-shaped mites. Most follicles were devoid of hair shafts and contained excess keratin. Samples of skin were sent to the University of Alberta for examination by an entomologist where the mites were identified as being of *Demodex* spp. similar to those described in white-tailed deer as *Demodex odocoilei*. Although this mule deer doe was infested with large numbers of *Demodex* spp., there was no detectable inflammatory response in the affected skin.

Mites of the genus *Demodex* (Acarina: Demodicidae) are normal inhabitants of the hair follicles and sebaceous glands of humans and all species of domestic animals. Little is known about the occurrence of these ectoparasites in wildlife. There are anecdotal descriptions of *Demodex* sp. in cervids from Europe, including red deer (*Cervus elaphus*), sika deer (*Cervus nippon*), roe deer (*Capreolus capreolus*) and Sambar deer (*Rusa unicolor*) (Bukva 1987 Folia Parasitologica. 34: 173-181). In North America, demodectid mites were first documented in 1971 on a white-tailed deer (*Odocoileus virginianus*) from Oklahoma (Carpenter et al. 1972, J of Wild. Dis. 8: 112-114). Recently, demodectid mites were found on Columbian black-tailed deer (*Odocoileus hemionus columbianus*) during investigation of a hair-loss syndrome in this species, a condition associated with chewing louse infestation and in which animals suffer from extensive hair loss, become progressively weaker and occasionally die (Bildfell

et al. 2004, J. of Wild. Dis. 40: 670-681). This is believed to be the first report of demodicosis in mule deer (*Odocoileus hemionus hemionus*).

Small numbers of *Demodex* mites are not usually detrimental to the host. However, when excessive proliferation of the parasite occurs, demodectic mange can result. While in some cases, particularly in cattle and dogs, demodectic mange can progress to a life-threatening disease, it is generally believed that factors such as poor nutrition, immunosuppression, accompanying disease or heredity are needed for demodicosis to become generalized and life threatening. In this case, it appeared that the animal died as a result of starvation, a condition compounded by the additional energy requirement for thermoregulation, as a result of heat loss associated with the extensive hair loss, impairing the animal's ability to survive the cold temperatures of winter and spring. Because the prevalence and intensity of infestation with demodectic mites in wild deer are largely unknown, it would be useful to systematically examine skin samples from cervids that are submitted for post-mortem examination, especially if they have some degree of abnormal hair loss.

Marie-Line Gentes¹, Heather Proctor², Gary Wobeser¹

¹ Canadian Cooperative Wildlife Health Centre, Department of Veterinary Pathology, Western College of Veterinary Medicine, University of Saskatchewan, 52 Campus Drive, Saskatoon, Saskatchewan, Canada S7N 5B4

² Department of Biological Sciences, University of Alberta, Edmonton, AB, Canada

Announcements

First Charitable Donation

In July 2006, a new chapter was opened in the evolution of the CCWHC when it received its first private charitable donation. This gift is in the form of a yearly grant from the Saskatoon Community Foundation made possible by a generous donation from the Bremner Family, long time residents and naturalists in the Saskatoon area. A special account has been established to hold this and other gifts and donations. These donations will be used to enable the CCWHC to undertake new initiatives to safeguard the health of Canada's wildlife, initiatives that can not be financed within the regular annual budget. We are most grateful to the Bremners for their pioneering gift to the CCWHC.

Download your newsletter from our Website

The CCWHC would like to inform you, by email, when our latest newsletter, (French and English), is available to download from our website. If you are interested in this service, please email Jacqui Brown at brownj@usask.ca to have your name placed on the notification list. Also, please inform us if you require only the electronic version or a printed copy as well.

